

Effects of Blast Overpressure on the Ear: Case Reports

David W. Chandler*
Charles V. Edmond†

Abstract

The case histories of five patients who experienced blast overpressure in excess of 200-dB peak pressure level are presented. Despite the significance of the sound pressure levels received in a military training accident and the severe injuries that resulted from the blast, these individuals experienced substantial improvement of hearing 1 year later. Undoubtedly, successful surgical intervention and medical management were the primary contributors to the restoration of hearing. Audiometric data are presented documenting hearing status within 2 to 3 weeks postinjury and following final surgical remediation of the resulting middle ear damage. A review of these cases offers insight into the possible prognosis of patients with similar injuries.

Key Words: Blast injury, postinjury, postoperative, tympanic membrane perforation, tympanoplasty

Blast injury of the ear is an uncommon occurrence and, consequently, has been sporadically reported. The infrequency of such reports and other confounding factors have yielded inconsistent audiologic findings for blast injury victims. For humans, accounts of blast trauma have largely been clinical reports resulting from warfare or exposure to explosions. Animal studies have been constrained by the difficulty in maintaining experimental controls for sound pressure levels (SPL) that exceed 185 to 190 dB. Despite these limitations, some general observations may be made regarding blast trauma to the ear.

The dynamics of a blast are characterized by a series of shock waves and displacement waves. Shock waves cause implosion and pressure changes that inflict injury to the body, particularly the gas containing organs. Otologic symptoms following blast injury to the ear include tinnitus, pain, vertigo, and hearing loss.

At noise levels exceeding 185-dB peak, rupture of the tympanic membrane will occur in about 50 percent of adults. At greater pressure levels, otologic and bodily injuries dramatically increase (Richmond et al, 1968; Kerr, 1978; Garinther and Kalb, 1983; Strohm, 1986; Casler et al, 1989; Stuhmiller, 1989). Readers interested in more detailed analysis of structural damage resulting from blast injury are referred to Kronenberg et al (1988), Zajtchuk and Phillips (1989), and Bruins and Cawood (1991). The focus of this report will be blast-induced hearing loss.

Typically, victims who are exposed to a blast wave experience severe hearing loss immediately postinjury (Singh and Ahluwalia, 1968; Teter et al, 1970; Ziv et al, 1973; Kerr and Byrne, 1975; Kerr, 1978, 1980; Pahor, 1981; Pratt et al, 1985; Axelsson and Hamernik, 1987; Cooper et al, 1989; Bruins and Cawood, 1991). This hearing loss can be conductive, mixed, or sensorineural depending upon the degree of injury to the ear. Following surgical repair of the middle ear or spontaneous recovery, hearing loss usually subsides within a few weeks, although the prevalence of permanent sensorineural loss ranges from 30 percent to 55 percent of the cases reported (Singh and Ahluwalia, 1968; Ziv et al, 1973; Kerr and Byrne, 1975; Kerr, 1978, 1980; Pahor, 1981; Pratt et al, 1985; Wolf et al, 1991). Permanent sensorineural hearing loss has been attributed to the intracochlear struc-

*U.S. Army Center for Health Promotion and Preventive Medicine—Europe, Landstuhl, Germany; †Department of Otolaryngology—Head & Neck Surgery, Madigan Army Medical Center, Tacoma, Washington

Reprint requests: David W. Chandler, U.S. Army Center for Health Promotion and Preventive Medicine—Europe (CHPPM-EUR), CMR 402, Box 88, Landstuhl, Germany, APO AE 09180-3619

tural damage that results from a blast (White et al, 1970; Hamernik et al, 1984a, b, 1986; Phillips et al, 1989; Roberto et al, 1989).

The following discussion summarizes the audiometric and otologic data for five individuals exposed to blast overpressure. This information offers insight to the management of similar injuries not often observed in clinical audiology practices.

CASE STUDIES

These case studies are the result of a training accident in which soldiers from a U.S. Army combat engineer unit were exposed to premature detonation of a 12-pound plastic explosive charge (\approx 24 sticks of dynamite) when the safety mechanism failed. Three soldiers were killed and the remaining individuals received multiple injuries. Five of the survivors were treated for over 1 year at Walter Reed Army Medical Center, Washington, DC, for injuries received from the blast, including bilateral ear damage.

All soldiers involved in this accident were reportedly positioned within 10 feet of the epicenter of a blast that exceeded a peak SPL of 200 dB. None of the soldiers were wearing hearing protection at the time of the accident. The reported locations of the five individuals regarding the epicenter of the blast are illustrated in Figure 1. Exposure levels from the blast estimated from a computer model at the Army Human Engineering Laboratory, Aberdeen, MD,

are also presented in Figure 1. Regarding the pressure values, pounds per square inch (psi) is the amount of force over an area, and intensity is represented in peak pressure level (dB PPL). The blast duration is defined by A-duration, which is the duration of the principle rise to the peak pressure and momentary return to ambient (Coles et al, 1968).

In the following section, the injuries sustained by each individual are described. There was no apparent connection between the degree of injury a soldier received and his distance from the blast. In all cases, however, injuries were generally more severe on the right side of the body; the reason for this is unknown.

All soldiers sustained bilateral perforated tympanic membranes and reportedly experienced hearing loss and vertigo immediately following exposure to the blast. At the time of their initial audiologic evaluation, each soldier had bilateral tympanic membrane perforations and continued to report hearing loss, although all reported that the vertigo had subsided. All soldiers further reported that they had no hearing loss prior to this incident.

Initial audiograms are presented for each case reflecting hearing status within 2 to 3 weeks postinjury, prior to surgical exploration or debridement of the ear. Postoperative audiograms completed 1 year later are also presented following surgical remediation. Hearing thresholds were determined by conventional audiometry using insert earphones (E-A-RTONE 3A) to increase interaural attenuation and reduce the need for masking. Bone-conduction testing was always completed and masking was used to obtain valid bone-conduction responses.

Case 1

Case 1 was a 20-year-old male who was located 3 to 5 feet in front of the blast. His injuries included amputation of both legs (above the right knee and below the left knee), an open fracture of the right hand with finger amputation, shrapnel injury to the right eye, and burns to his upper body.

Otologic injuries included traumatic rupture of both tympanic membranes. The initial audiogram postinjury revealed a bilateral mild to moderate hearing loss at all test frequencies (Fig. 2A). The loss was largely conductive with the air-bone gap ranging from 20 to 40 dB, although a sloping sensorineural loss was evident at 2000 to 8000 Hz for the right ear. A sloping high-frequency hearing loss was also present

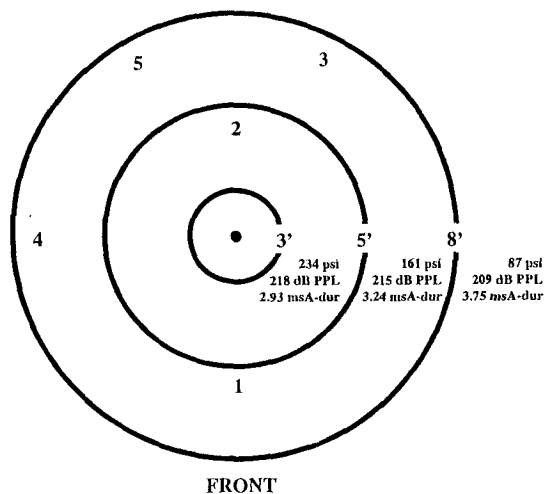


Figure 1 Location of soldiers re: epicenter of the blast, and computed exposure levels (source: Army Human Engineering Laboratory, Aberdeen, MD).

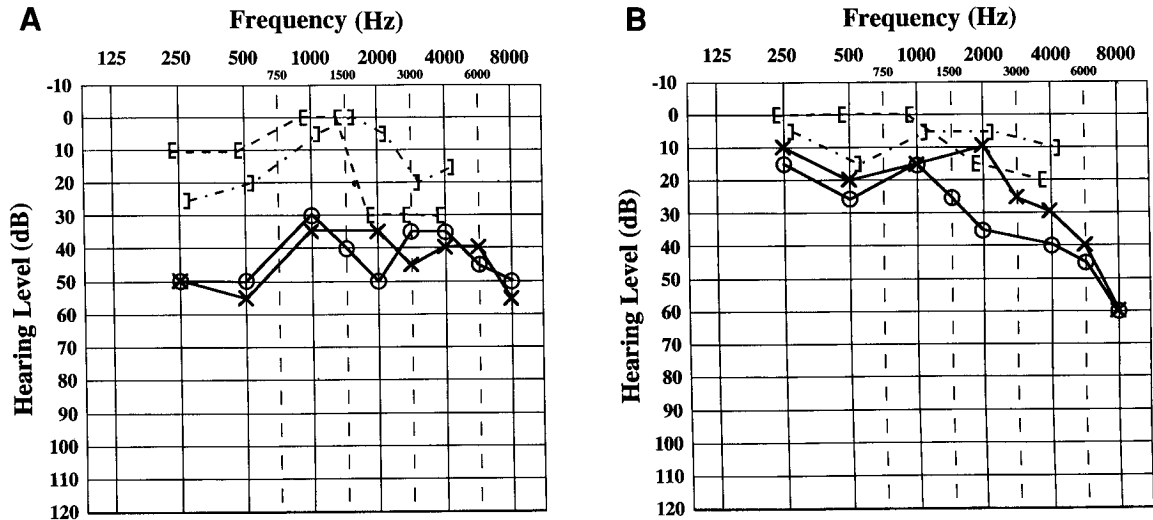


Figure 2 A, initial audiogram for Case 1 completed 19 days postinjury. B, postoperative audiogram for Case 1 completed 1 year postinjury.

in the left ear at 6000 to 8000 Hz that was likely sensorineural and secondary to blast injury.

Surgical exploration of the right ear was completed 60 days after injury. A medialized malleus with only a remnant of incus was noted, and this patient underwent ossicular chain reconstruction and tympanoplasty for the right ear. Exploration of the left middle ear was completed 9 months postinjury; the ossicular chain was found to be intact and a tympanoplasty was completed.

Audiologic evaluation 1 year postinjury (see Fig. 2B) showed considerable improvement in hearing bilaterally. Thresholds were normal at 250 to 3000 Hz for the left ear and normal through 1500 Hz for the right ear. A mild to moderate hearing loss was present at all other test frequencies. This loss was judged to be primarily conductive through 4000 Hz based on normal bone-conduction threshold values, although a sensorineural loss could not be ruled out at 6000 to 8000 Hz.

Case 2

The second soldier was a 20-year-old male who was located 3 to 4 feet behind the blast. He sustained multiple shrapnel wounds to all limbs, a broken left tibia, intraocular injury to his right eye, a collapsed right lung, and burns to his upper body.

Otologically, both tympanic membranes demonstrated total traumatic perforations. This patient initially presented a moderate to severe

hearing loss at 250 to 500 Hz and a mild to moderate hearing loss at all other test frequencies bilaterally (Fig 3A). The loss was primarily conductive at 250 to 4000 Hz, except for mild sensorineural involvement in the left ear at 3000 Hz. As with Case 1, the bilateral hearing loss evident at 6000 to 8000 Hz was likely sensorineural and secondary to blast injury.

Right middle ear surgery 60 days postinjury revealed a partial fracture of the anterior crura of the stapes, and a Type I tympanoplasty was completed. Follow-up exploration of the right middle ear 6 months later revealed minimal squamous debris along the medial aspect of the malleus and significant stapes superstructure damage. Marked erosion of the anterior and posterior crus was noted, along with a mobile footplate. This ossicular defect was corrected by removing the remnants of the stapes superstructure and placing a Robinson prosthesis (stapedectomy).

Left middle ear exploration 7 months postinjury revealed a perforated tympanic membrane and marked adhesions and granulation tissue about the stapes. A Type I tympanoplasty was completed for the left ear.

One year postinjury, this patient showed a mild hearing loss above 4000 Hz in the left ear and a mild to moderate loss above 2000 Hz in the right ear (see Fig. 3B). Bone-conduction thresholds indicated that this loss was primarily conductive (through 4000 Hz), as evidenced by a significant air-bone gap. Hearing at 6000 to 8000 Hz was slightly improved in the left ear from the initial audiogram; right ear thresholds

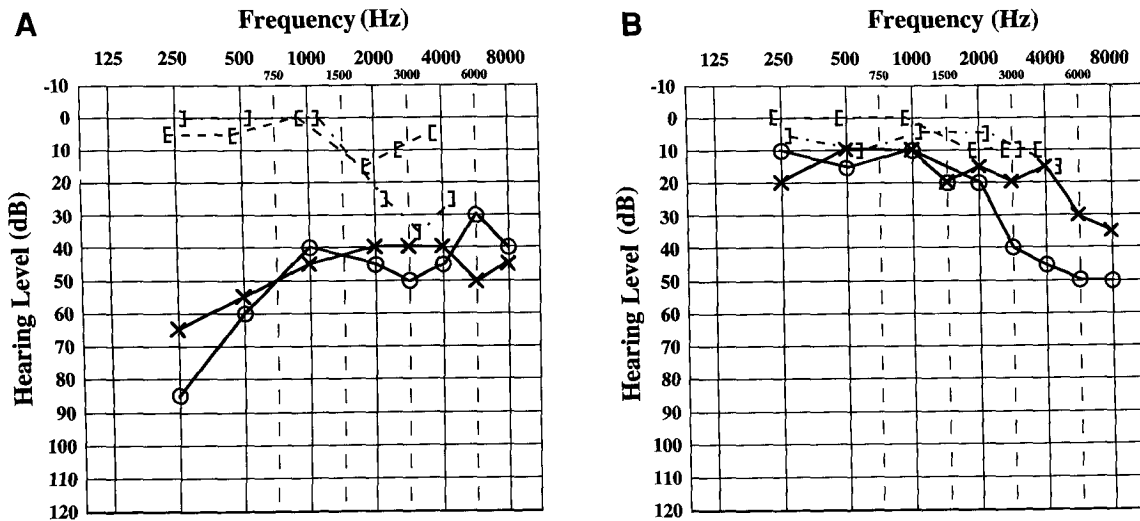


Figure 3 A, initial audiogram for Case 2 completed 16 days postinjury. B, postoperative audiogram for Case 2 completed 1 year postinjury.

at these frequencies were slightly worse than previously recorded.

Case 3

This individual was a 24-year-old male who was located 4 to 6 feet to the right, rear of the blast. His right leg was amputated below the knee, and his left leg was fractured at the tibia and fibula. He also suffered a fractured right wrist and hand, multiple shrapnel wounds to the chest and abdomen, intraocular injury of the right eye, and burns to his upper body.

Otologic examination revealed bilateral complete tympanic membrane perforations. Despite

the apparent absence of more traumatic middle ear injury, this soldier displayed a severe mixed hearing loss at all test frequencies in both ears 2 weeks postinjury (Fig. 4A). Subsequent operative middle ear explorations 2 months postinjury for the right ear and 4 months postinjury for the left ear failed to show any significant ossicular chain damage. Both tympanic membrane perforations were closed in a standard fashion (Type I tympanoplasty).

This patient's hearing was marginally normal through 3000 Hz for both ears 1 year postinjury (see Fig. 4B). Hearing improved in the high frequencies, bilaterally, from the initial audiogram. A moderate hearing loss remained above

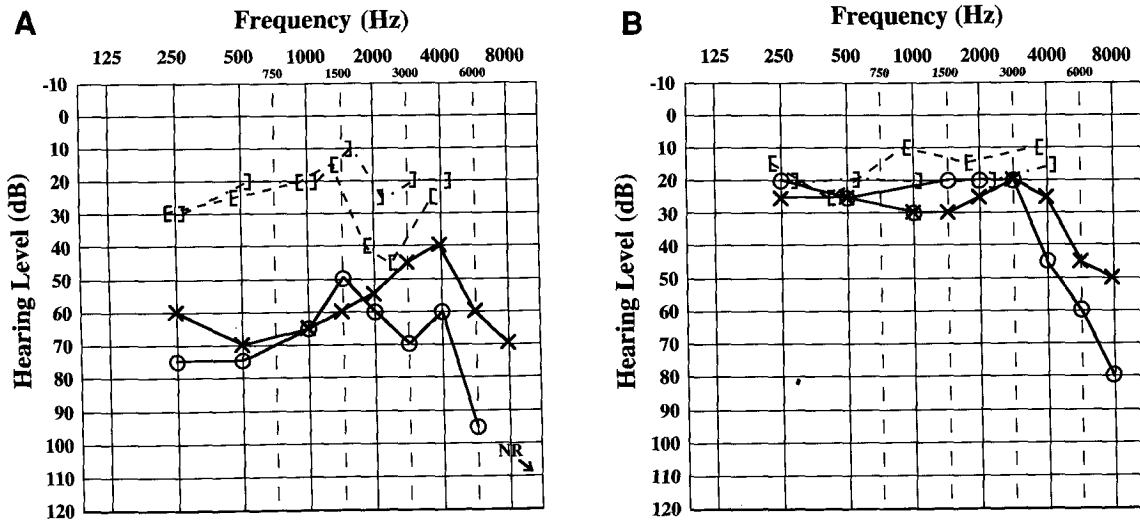


Figure 4 A, initial audiogram for Case 3 completed 19 days postinjury. B, postoperative audiogram for Case 3 completed 9 months postinjury.

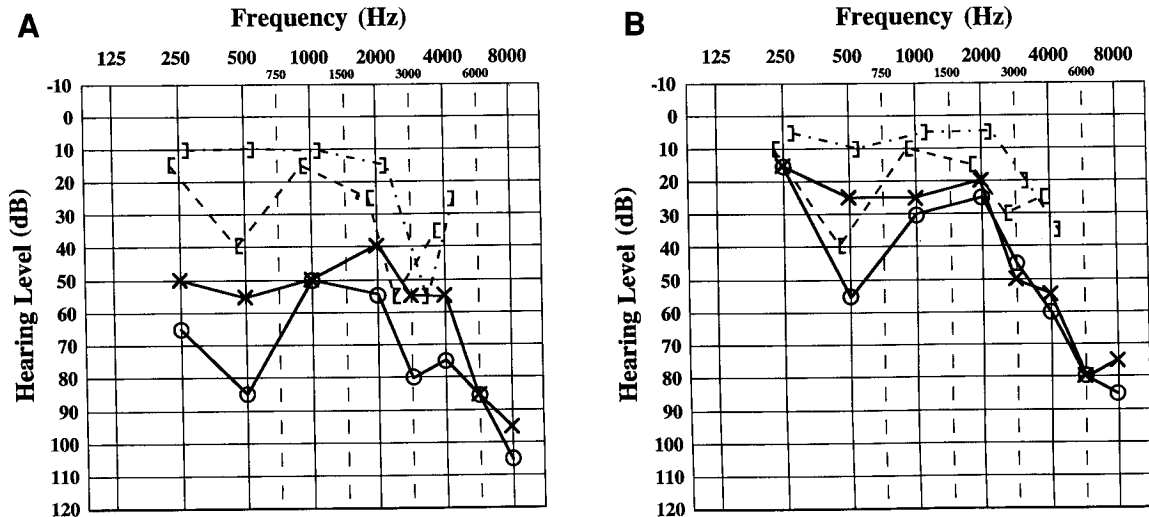


Figure 5 A, initial audiogram for Case 4 completed 18 days postinjury. B, postoperative audiogram for Case 4 completed 8 months postinjury.

4000 Hz in the left ear, and the right ear showed a moderate to severe loss at 4000 to 8000 Hz.

Case 4

This soldier was a 27-year-old male who was located 6 to 8 feet to the left of the blast. His left leg was amputated above the knee, and he suffered bilateral collapsed lungs and burns to all of his limbs.

Upon initial evaluation, this patient exhibited a severe mixed hearing loss in the right ear and a moderate to severe, primarily conductive loss in the left ear (Fig. 5A). Both tympanic membranes demonstrated complete traumatic perforations. Middle ear exploration of the right ear at 2 months postexposure and the left ear at 4 months postexposure revealed bilateral ossicular discontinuity with absent incus. Initial treatment consisted of closure of the total perforations by Type I tympanoplasty. Follow-up exploratory surgery and ossicular reconstruction was planned 9 months to 1 year following initial surgery.

Audiologic testing 1 year postinjury continued to show significant bilateral hearing loss (see Fig. 5B). This loss was primarily conductive below 6000 Hz, except for isolated frequencies (500 Hz and 3000 Hz, right ear; 4000 Hz, left ear). A severe bilateral hearing loss remained at 6000 to 8000 Hz. Additional evaluative and reconstructive procedures were scheduled outside of our medical center.

Case 5

The final case report was a 20-year-old male who was located 6 to 7 feet to the left, rear of the blast. The femoral artery of his right leg was severed, and he received multiple shrapnel wounds to his chest and abdomen and an intraocular injury to the right eye.

Upon initial audiologic evaluation, this patient presented a mild to moderate hearing loss in his left ear and a moderate to severe hearing loss in his right ear (Fig. 6A). This loss was primarily conductive for the left ear and mixed for the right ear.

Middle ear exploration of the right ear 3 months after injury revealed complete tympanic membrane rupture and lateral displacement of his right malleus with disarticulation at the incudostapedial joint. Repair was completed by Type I tympanoplasty. Exploratory surgery of the left ear completed 8 months postinjury revealed a medialized malleus, although the ossicular chain remained intact.

One year postinjury, this soldier's hearing had improved to normal in the left ear, except for a moderate loss at 6000 to 8000 Hz (see Fig. 6B). Hearing also improved in his right ear below 4000 Hz, but he continued to present a mild conductive loss at 1500 to 2000 Hz, with a significant air-bone gap at 250 to 2000 Hz. A mild to severe mixed hearing loss remained evident in the right ear at 3000 to 8000 Hz. Follow-up reconstruction surgery was planned for the right ear.

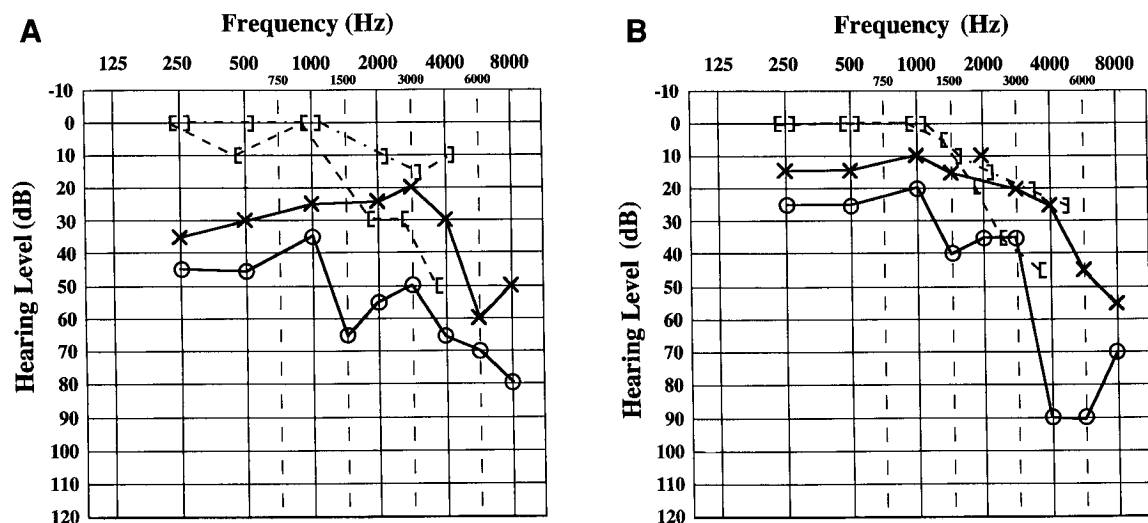


Figure 6 A, initial audiogram for Case 5 completed 14 days postinjury. B, postoperative audiogram for Case 5 completed 14 months postinjury.

DISCUSSION

If the improved hearing recorded for these five individuals is at all representative of similar trauma to the ear, then the prognosis of hearing health for such injuries is excellent with successful surgical and medical intervention. However, these case reports illustrate the challenge presented to the audiologist regarding evaluation and management of victims of blast overpressure. Interpretation of the initial audiograms for these patients was complicated by the presence of large air-bone gaps, which made masking difficult. Despite this complication, valuable clinical observations can be made from these cases.

First, these patients showed considerable improvement in hearing between their initial (postinjury) and final audiograms. Hearing was generally poorer at frequencies above 2000 Hz (except in the right ear of Case 4) and was usually worse in the right ear. The hearing loss recorded on the final audiograms for these cases was largely conductive at 250 to 4000 Hz, as determined from air-bone gaps that averaged 10 to 25 dB. A mixed loss was observed at isolated frequencies in some cases (Cases 4 and 5).

Apart from the conductive component, all cases have a bilateral hearing loss at 6000 to 8000 Hz that is likely sensorineural. The change in thresholds between the initial and final audiograms varied at these frequencies. In some cases (Cases 3 and 4), hearing improved at 6000 to 8000 Hz from the initial audiogram, while in other cases, hearing was unchanged or poorer

at these frequencies. Nevertheless, in all cases, these soldiers had poorer hearing, postoperatively, than that of their contemporaries in the same job (Chandler and Fletcher, 1983).

The conductive hearing loss and relative absence of sensorineural hearing loss below 4000 Hz observed in these cases are likely due to the disruption of the conductive pathway during the blast. Evidence from bioengineering models of the ear suggests that a critical time window exists in which energy is transferred from the middle ear to the inner ear (Price and Kalb, 1991). According to such modeling, upward movements of the basilar membrane produce the stresses that are the primary cause of damage. Furthermore, the clipping introduced by the annular ligament of the stapes might influence the direction of the basilar membrane. As a result, a blast of sufficient duration in an intact ossicular chain pushes the stapes in and holds it in place, effectively blocking transmission into the inner ear during a critical "period of vulnerability" when hearing loss may be more extreme.

This modeled energy transmission information is consistent with the limited sensorineural hearing loss below 4000 Hz in the cases presented in this report. With disruption of the tympanic membrane and/or ossicular chain, a dissipation of energy occurred. Obviously, these cases were not completely spared cochlear damage as evidenced by the sensorineural hearing loss above 4000 Hz. However, the interruption in sound transmission possibly lessened more extensive cochlear damage by

reducing the efficiency of transmission of mechanical energy to the oval window. Similar accounts have been reported by other investigators (Pearlman, 1945; Hamernik and Henderson, 1974; Eames et al, 1975).

With regard to otologic complaints other than hearing loss, all of these patients reported vertigo, otalgia, and tinnitus immediately following the blast. At the time of their initial audiologic evaluation, all patients reported that the vertigo and otalgia had subsided, although they all continued to experience tinnitus and hearing loss. It should be noted that, aside from the hearing loss associated with the blast injury, some clinical reports detail delayed structural changes in the middle ear and cochlea occurring in the years following a blast overpressure injury (see Zajtchuk and Phillips [1989] for review). Such changes include cholesteatoma formation, perilymphatic fistula, and deterioration of the ossicular chain.

Cholesteatoma formation can be attributed to squamous epithelium that becomes trapped within the middle ear secondary to either inverted edges of the original perforation, or to epithelial cells that were imploded into the middle ear cleft. Case 2 in our series is an example of cholesteatoma formation noted upon re-exploration for ossicular reconstruction.

Perilymphatic fistula formation resulting from blast overpressure is a rare finding. However, any patient who exhibits continued vertigo and/or fluctuating hearing loss should be evaluated for a perilymphatic fistula at either the oval or round window. Disruption of the annular ligament or fracture of the stapes footplate could contribute to perilymphatic fistula formation.

Latent ossicular chain deterioration has not been reported to our knowledge. However, in Case 2, re-exploration demonstrated significant ossicular erosion not present during the primary repair. This ossicular wasting might be attributed to disruption of the tenuous vascular supply to the ossicles, resulting in an avascular necrosis. In patients that demonstrate significant postoperative air-bone gap in follow-up audiologic evaluations, consideration for ossicular deterioration should be made.

The cases presented in this report underscore the importance of the audiologist in medical management of patients exposed to blast injury. Despite the extreme otologic damage associated with blast injury, the prognosis for substantial improvement in hearing can be good with successful medical intervention.

Acknowledgments. We wish to express our gratitude to Joel Bales, Mary Cord, Catherine Jons, Mike Moul, Linda Reiter, Therese Robier, Rauna Surr, Joan Tendrich, and the staff at the Army Audiology & Speech Center, Walter Reed Army Medical Center, who were instrumental in documenting these cases over a 15-month period. Appreciation is also extended to William Beck for his comments on an earlier version of this paper.

REFERENCES

- Axelsson A, Hamernik R. (1987). Acute acoustic trauma. *Acta Otolaryngol (Stockh)* 104:225-233.
- Bruins W, Cawood R. (1991). Blast injuries of the ear as a result of the Peterborough lorry explosion: 22 March 1989. *J Laryngol Otol* 105:890-895.
- Casler J, Chait R, Zajtchuk J. (1989). Treatment of blast injury to the ear. *Ann Otol Rhinol Laryngol Suppl* 140; 98(5):13-16.
- Chandler D, Fletcher J. (1983). Comparison of occupational hearing losses among military engineers and their civilian counterparts. *J Audit Res* 23:241-250.
- Coles R, Garinther G, Hodge D, Rice C. (1968). Hazardous exposure to impulse noise. *J Acoust Soc Am* 43:336-346.
- Cooper G, Maynard R, Cross H, Hill J. (1989). Casualties from terrorist bombings. *J Trauma* 23:955-967.
- Eames B, Hamernik R, Henderson D, Feldman A. (1975). The role of the middle ear in acoustic trauma from impulses. *Laryngoscope* 85:1582-1592.
- Garinther G, Kalb J. (1983). An acoustical assessment of the impulse noise of grenade simulators exploding in inclosures. *Hum Eng Lab Tech Mem* 9-83; 1-37.
- Hamernik R, Henderson D. (1974). Impulse noise trauma. *Arch Otolaryngol* 69:118-121.
- Hamernik R, Turrentine G, Roberto M. (1986). Mechanically induced morphological changes in the organ of Corti. In: Salvi R, Henderson D, Hamernik R, Colletti V, eds. *Basic Applied Aspects of Noise-Induced Hearing Loss*. New York: Plenum Press, 69-83.
- Hamernik R, Turrentine G, Roberto M, Salvi R, Henderson D. (1984a). Anatomical correlates of impulse noise-induced mechanical damage to the cochlea. *Hear Res* 13:229-247.
- Hamernik R, Turrentine G, Wright C. (1984b). Surface morphology of the inner sulcus and related epithelial cells of the cochlea following acoustic trauma. *Hear Res* 16:143-160.
- Kerr A. (1978). Blast injuries to the ear. *Practitioner* 221:677-682.
- Kerr A. (1980). Trauma and the temporal bone. *J Laryngol Otol* 94:107-110.
- Kerr A, Byrne J. (1975). Blast injuries of the ear. *BMJ* 1:559-561.
- Kronenberg J, Ben-Shoshan J, Modan M, Leventon G. (1988). Blast injury and cholesteatoma. *Am J Otol* 9:127-130.

- Pahor A. (1981). The ENT problems following the Birmingham bombings. *J Laryngol Otol* 95:399-406.
- Pearlman H. (1945). Reaction of human conduction mechanism to blast. *Laryngoscope* 55:427-443.
- Phillips Y, Mundie T, Hoyt R, Dodd K. (1989). Middle ear injury in animals exposed to complex blast waves inside an armored vehicle. *Ann Otol Rhinol Laryngol Suppl* 140; 98(5):17-22.
- Pratt H, Goldsher M, Netzer A, Shenhav R. (1985). Auditory brainstem evoked potentials in blast injury. *Audiology* 24:297-304.
- Price G, Kalb J. (1991). Insights into the hazard from intense impulses from a mathematical model of the ear. *J Acoust Soc Am* 90:219-227.
- Richmond D, Damon E, Fletcher E, Bowen I, White C. (1968). The relationship between selected blast-wave parameters and the response of mammals exposed to air-blast. *Ann N Y Acad Sci* 152:103-121.
- Roberto M, Hamernik R, Turrentine G. (1989). Damage of the auditory system associated with acute blast trauma. *Ann Otol Rhinol Laryngol Suppl* 140; 98(5):23-34.
- Singh D, Ahluwalia K. (1968). Blast injuries of the ear. *J Laryngol Otol* 82:1017-1028.
- Strohm M. (1986). Tympanic membrane lesions. In: Karger S, ed. *Trauma of the Middle Ear: Advances in Oto-Rhino-Laryngology*. Basel, Switzerland: 6-71.
- Stuhmiller J. (1989). Use of modeling in predicting tympanic membrane rupture. *Ann Otol Rhinol Laryngol Suppl* 140; 98(5): 53-60.
- Teter D, Newell R, Aspinall K. (1970). Audiometric configurations associated with blast trauma. *Laryngoscope* 80:1122-1132.
- White C, Bowen I, Richmond D. (1970). The relation between eardrum failure and blast-induced pressure variations. *Space Life Sci* 2:158-205.
- Wolf M, Kronenberg J, Ben-Shoshan J, Roth Y. (1991). Blast injury of the ear. *Military Med* 156:651-653.
- Zajtchuk J, Phillips Y. (1989). Effects of blast overpressure on the ear. *Ann Otol Rhinol Laryngol Suppl* 140: 98(5).
- Ziv M, Philipsohn N, Leventon G, Man A. (1973). Blast injury of the ear: treatment and evaluation. *Military Med* 138:811-813.